Body Contouring: Liposuction and Non-invasive Modalities

156

Kyle M. Coleman and William P. Coleman III

Chapter Contents

Consultation 2667
Liposuction 2667
Liposuction Instrumentation 2671
Liposuction Variations 2672
Non-Cosmetic Liposuction 2672
Postoperative Care 2673
Complications of Liposuction. 2673
Non-invasive Body Contouring. 2673
Cellulite 2675

Synonyms: ▪ Liposculpture ▪ Tumescent liposuction ▪ Lipoplasty ▪ Lipolysis

Key features

- Liposuction is indicated for spot reduction of localized adiposities
- Liposuction is ideally suited for healthy patients who are near their ideal body weight
- The tumescent local anesthetic technique is the safest approach to anesthesia for liposuction
- Non-invasive technologies offer the benefits of less downtime compared to liposuction
- Careful selection of the appropriate treatment for each patient is necessary to achieve the best results

INTRODUCTION AND BACKGROUND

Liposuction is an effective method for surgically improving localized areas of excess subcutaneous fat. Liposuction has undergone many changes since initial reports in the late 1970s[1–3]. Modern liposuction is performed using dilute local anesthesia, via the tumescent technique, together with small cannulas connected to a vacuum aspirator. When performed correctly using the tumescent techniques, liposuction can be safely performed in an office setting with very few complications. Substantial amounts of fat can be aspirated with minimal blood loss and excellent aesthetic results. Patient selection remains paramount in achieving good results.

Liposuction is currently among the most common invasive cosmetic procedures performed in the US. However, recent survey data have shown a decrease in the number of liposuctions being performed. This is likely due to the increased availability of non-invasive technologies that are currently approved by the FDA for the treatment of localized adiposity. These technologies generally have fewer side effects than tumescent liposuction but deliver more modest results. When choosing between liposuction and non-invasive treatments, it is important that patients have realistic expectations.

CONSULTATION

As with any other medical or surgical consultation, a pertinent review of past medical history, medications, and allergies is essential. The review of systems should be comprehensive enough to exclude any underlying abnormalities which would preclude or modify treatments[4]. Social and psychiatric histories may reveal details which would make the patient an inappropriate candidate for cosmetic treatments.

The physical examination for body contouring should be performed with the patient completely unclothed in the body areas of concern to them. The patient should be examined standing up so that the full effects of gravity are apparent. Physical examination consists of both observation and palpation to reveal the thickness and firmness of underlying fatty tissue. The physician should look for asymmetries, scars, hernias, musculoskeletal abnormalities, dimples, skin laxity, and overlying cutaneous lesions. During this examination, it is important to point out any of these features that may affect results. This will add to the patient's understanding about what may or may not be able to be achieved through body contouring procedures. It is important to accurately describe individual body parts in words that the patient will understand. A diagram of typical anatomic sites may prove helpful (see Fig. 156.6). Also, it is important to remember that patients have a different vantage point; photography and/or full-length mirrors may be helpful during the consultation to ensure their understanding.

A frank discussion about the patient's goals should also be had; many patients have unrealistic expectations with regard to body contouring procedures. Patients should also appreciate the pros and cons of the currently available options for body contouring. Patients undergoing non-invasive treatments must understand that results are inferior to tumescent liposuction and that multiple treatments will likely be required. Patients undergoing liposuction procedures must recognize the surgical risks as well as the need for external compression garments.

The presence of obesity and/or poor muscle tone are warning signs that the patient may not be an appropriate candidate. Generally, obese patients do not make good candidates for body contouring procedures. These patients may have underlying disorders that place them at higher procedural risk; also, due to their excess weight, these procedures will often create minimal, if any, improvement.

Occasionally, patients, mostly male, present with a large amount of visceral fat. Palpation of the abdominal tissues reveals a firm underlying musculature with very little fat on the pinch test. These patients are not only poor candidates for body contouring procedures but are also at increased risk for cardiovascular disease. It is important to recommend consultation with a primary care physician and appropriate nutritional experts.

LIPOSUCTION

Indications and Contraindications

Tumescent liposuction is indicated for improving localized adiposities. Certain areas of subcutaneous fat are often not fully responsive to diet and exercise alone, and there are no exercises capable of spot reduction of adiposity.

Most liposuction patients complain that the troublesome areas of fat excess "run in the family". Furthermore, areas of excess subcutaneous fat can be resistant to caloric restriction or exercise. Tumescent liposuction is able to specifically target these localized areas of excess subcutaneous fat as a complement to, not a replacement for, diet and exercise.

Downloaded for Anonymous User (n/a) at Egyptian Knowledge Bank from ClinicalKey.com by Elsevier on March 10, 2024. For personal use only. No other uses without permission. Copyright ©2024. Elsevier Inc. All rights reserved.

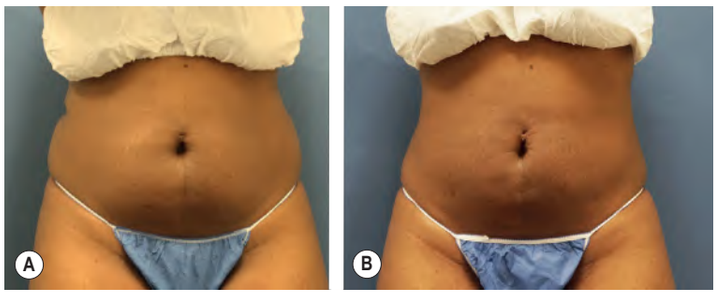

Fig. 156.1 Liposuction of the upper and lower abdomen. A Preoperative. **B** Postoperative, showing improved contours. *Courtesy K.M. Coleman, MD.*

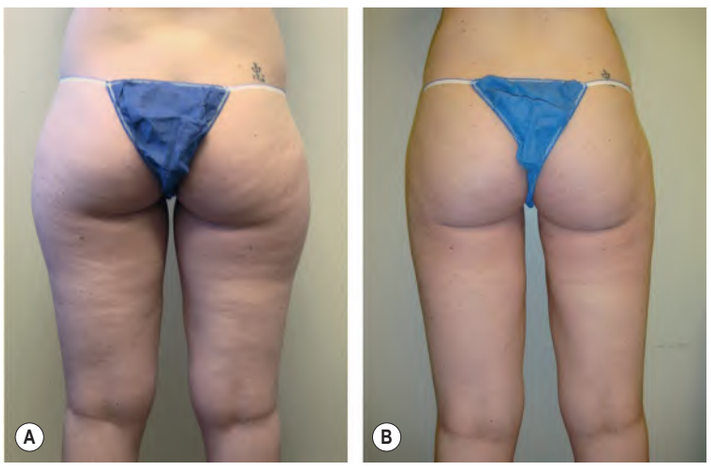

Fig. 156.2 Liposuction of the inner and outer thighs and hips. A Preoperative. **B** Postoperative, showing improved contours. *Courtesy K.M. Coleman, MD.*

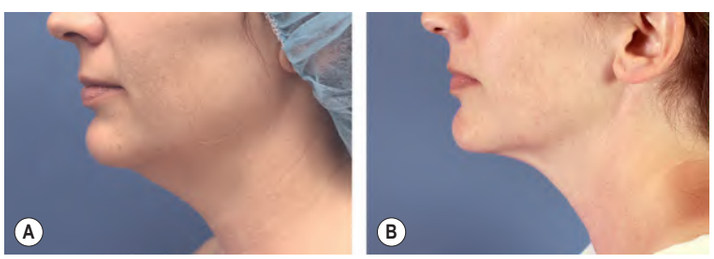

Fig. 156.3 Liposuction of the neck and jowls. A Preoperative. **B** Postoperative, showing improved appearance. *Courtesy K.M. Coleman, MD.*

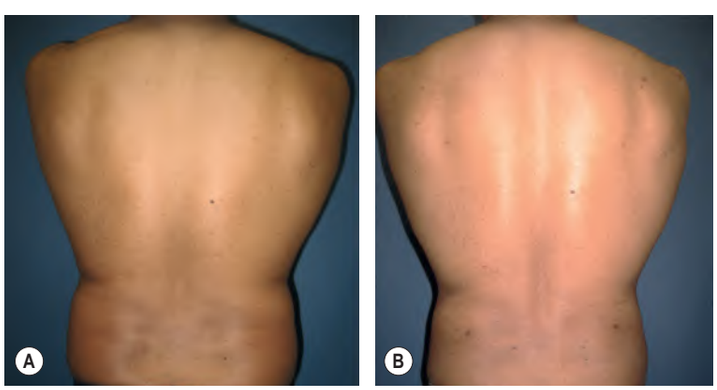

Fig. 156.4 Liposuction of male flanks. A Preoperative. **B** Postoperative, showing the improvement. *Courtesy K.M. Coleman, MD.*

Liposuction can be used to treat localized areas of adiposities throughout the body. Common areas improved by liposuction include the abdomen (Fig. 156.1) and inner and outer thighs (Fig. 156.2). Other sites include the neck and jowls (Fig. 156.3), male and female breasts, back, flanks (Fig. 156.4), hips (Fig. 156.2), buttocks, upper arms, knees (Fig. 156.5), calves, and ankles (Fig. 156.6). Genetic predisposition determines the location of excess fat storage in each individual.

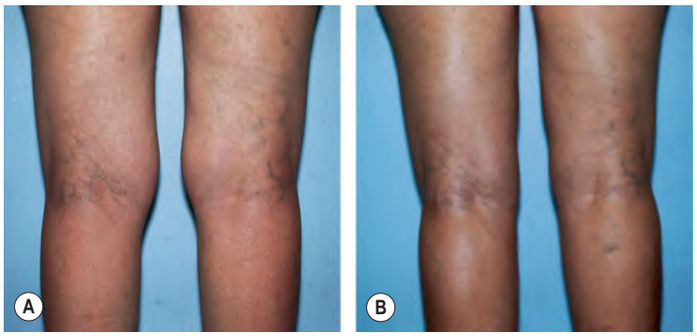

Fig. 156.5 Liposuction of the medial knees. A Preoperative. **B** Postoperative, showing more even contours. *Courtesy W.P. Coleman III, MD.*

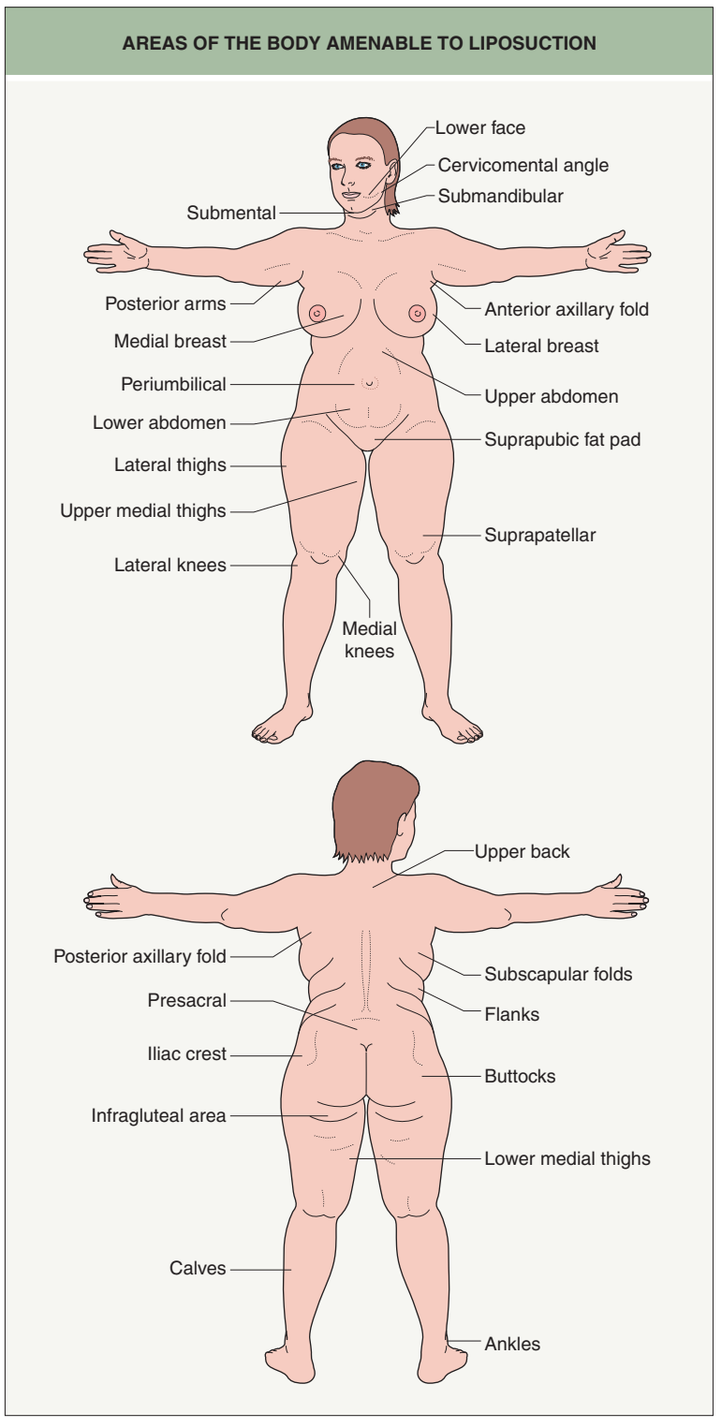

Fig. 156.6 Areas of the body amenable to liposuction.

Downloaded for Anonymous User (n/a) at Egyptian Knowledge Bank from ClinicalKey.com by Elsevier on March 10, 2024. For personal use only. No other uses without permission. Copyright ©2024. Elsevier Inc. All rights reserved.

NON-COSMETIC INDICATIONS FOR LIPOSUCTION
Lipomas
Familial multiple lipomatosis
Adiposis dolorosa (Dercum disease)
Gynecomastia
Pseudogynecomastia
Insulin-induced lipohypertrophy
"Buffalo hump" due to Cushing syndrome
Lipodystrophy in HIV-infected patients
Axillary hyperhidrosis (Fig. 156.7)
Flap undermining
Lymphedema following axillary lymphadenectomy

Table 156.1 Non-cosmetic indications for liposuction. ART, antiretroviral therapy.

Fig. 156.7 Superficial liposuction of the axilla is performed for improvement of hyperhidrosis. *Courtesy W.P. Coleman III, MD.*

In general, operating on over 10% of the body increases liposuction risks. Guidelines of care published by dermatologic organizations recommend fat extractions of less than 4500–5000 ml[5,6]. This volume should be considered as an uppermost limit; beyond this, profound fluid shifts may occur, resulting in cardiovascular compromise. Many experienced liposuction surgeons rarely, if ever, remove anywhere near 5000 ml in a single session. Larger extractions also necessitate larger infiltrations of local anesthetics. When the tumescent technique is employed, guidelines of care recommend not exceeding a lidocaine dose of 55 mg/kg[7–10]. In slender patients, this should probably be adjusted down to 45 mg/kg. These dose limits also restrict the number of areas that can be treated during a single liposuction procedure.

If, in the physician's judgment, it is risky to treat all of the areas that concern the patient, serial liposuction should be recommended. These separate surgeries can be spaced days or months apart, according to the patient's preference.

Non-cosmetic indications for liposuction include pseudogynecomastia and aspiration of lipomas[11–13] (Table 156.1). Liposuction can be effective for debulking larger tumors with a minimal scar. It can also be used as an alternative for treating axillary hyperhidrosis by destroying eccrine and apocrine glands (Fig. 156.7)[13].

Contraindications are outlined in Table 156.2.

The Preoperative Visit

A carefully planned preoperative visit is usually scheduled two or more weeks prior to the actual date of the surgery. Generally, a complete blood count and a complete metabolic profile are obtained; a prothrombin time and partial thromboplastin time may be indicated based on history. Some physicians also perform a urinalysis and tests for infectious diseases such as viral hepatitis and HIV.

Detailed pre- and postoperative instructions should be provided to the patient during this visit. Preoperative instructions should include a list of over-the-counter medications that should be avoided. Aspirin, non-steroidal anti-inflammatory drugs (e.g. ibuprofen), vitamin E, fish oil, and alcohol are common anticoagulants that patients should carefully avoid preoperatively. Herbal remedies may also have anticoagulant activity and should be avoided for 2 weeks preoperatively.

CONTRAINDICATIONS TO TUMESCENT LIPOSUCTION
Absolute
Severe obesity
Individuals seeking liposuction as a weight-loss procedure
Body dysmorphic syndrome
Untreated psychiatric illness
Excessive scarring in the areas to be improved
Hernia in area of proposed treatment
Relative
Moderate obesity
Poor wound healing (including Ehlers–Danlos syndrome)
Hypertrophic or keloidal scarring
Coagulation or bleeding disorders
Allergy to lidocaine
Adverse reaction to epinephrine (e.g. tachycardia)
Significant medical illnesses
Unstable psychiatric illnesses
Hernia in area of proposed treatment

Table 156.2 Contraindications to tumescent liposuction.

Drugs that affect the hepatic cytochrome P450 system should be discontinued if possible (see later). In addition, patients should be counseled about proper nutrition. Trying to lose weight rapidly or eating excessively should both be discouraged. Some patients benefit from nutritional counseling on a pre- and postoperative basis.

Description of Techniques

Tumescent anesthesia

The technique of using tumescent local anesthesia for liposuction was developed by the dermatologist Dr Jeffrey Klein. In 1987, Klein published his technique for the infiltration of a dilute solution of lidocaine with epinephrine (adrenaline) into fat, allowing for liposuction to be performed under local anesthesia[7]. Due to significantly reduced bleeding, the previous common complications of seroma and hematoma became uncommon[14]. Bruising was also minimized. The procedure has proven to be remarkably safe.

Klein demonstrated that dilute concentrations of lidocaine with epinephrine are not absorbed into the circulation to the same degree as higher 1%–2% concentrations of lidocaine, even when the total doses are equal. He confirmed that using only dilute solutions of lidocaine with epinephrine safely allowed lidocaine dosages of up to 35 mg/kg body weight[8]. This advance allowed larger amounts of fat to be removed with only local anesthesia.

A typical tumescent anesthetic formulation is shown in Table 156.3. Dilute solutions of lidocaine with epinephrine provide safe local anesthesia with excellent vasoconstriction. Sodium bicarbonate is added to adjust the solution to a more physiologic pH. The combination of a dilute solution of lidocaine with the vasoconstrictive effect of epinephrine ensures minimal systemic absorption of lidocaine[15].

The tumescent technique provides a number of advantages (Table 156.4). Local anesthesia persists for up to 24 hours after tumescent liposuction, reducing the need for postoperative analgesia[16]. The extensive vasoconstriction produced by dilute epinephrine reduces the volume of whole blood for each liter of pure fat removed by liposuction to less than 12 ml[14,16]. With rapid postoperative recovery, patients can return to their normal lives quickly. Improved aesthetic results are also seen with tumescent liposuction because smaller cannulas can be used, reducing irregularities of the skin[17].

An important advantage is the decrease in anesthetic risk observed with tumescent anesthesia for liposuction, as compared to intravenous or general anesthesia[18–21]. Systemic anesthesia can be associated with a significant risk of serious complications[22]. More recent research has indicated that the maximum safe dosage of lidocaine, when used with the tumescent technique for liposuction, is 55 mg/kg[9,10]. Klein recommends an upper limit of 45 mg/kg for thinner individuals[17].

Fresh tumescent anesthetic solution must be correctly and carefully prepared in a sterile fashion prior to each procedure by a trained healthcare professional. Standardization is important in order to avoid confusion and limit risk. The concentration of lidocaine or epinephrine can be varied depending on the anatomic site. The standard formula of

Downloaded for Anonymous User (n/a) at Egyptian Knowledge Bank from ClinicalKey.com by Elsevier on March 10, 2024. For personal use only. No other uses without permission. Copyright ©2024. Elsevier Inc. All rights reserved.

TYPICAL TUMESCENT ANESTHETIC FORMULATION (LIDOCAINE 0.05%, EPINEPHRINE 1 : 1 000 000)
50 ml 1% plain lidocaine (500 mg)
1 ml 1 : 1000 epinephrine from ampule (1 mg)
10 ml sodium bicarbonate (8.4% $NaHCO_3$ solution)
1 liter normal saline (0.9% NaCl solution)

Table 156.3 Typical tumescent anesthetic formulation (lidocaine 0.05%, epinephrine 1 : 1 000 000).

ADVANTAGES OF TUMESCENT LIPOSUCTION
Complete regional anesthesia without the need for nerve blocks
Local anesthesia persists for up to 24 hours, reducing the need for postoperative analgesia
Minimizes blood loss
Minimal postoperative ecchymoses
Rapid postoperative recovery
Smaller cannulas can be used, reducing skin irregularities
Decreased anesthetic risk compared to intravenous or general anesthesia

Table 156.4 Advantages of tumescent liposuction.

0.05% lidocaine with 1 : 1 000 000 epinephrine plus sodium bicarbonate works well for most sites (see Table 156.3). Occasionally, fibrous areas such as the periumbilical area or breast require a higher concentration of lidocaine, up to 0.1%.

Proper infiltration of tumescent anesthesia is important. The skin is prepped with an antimicrobial scrub. Insertion sites for the infiltration needles are anesthetized with small wheals of 1% lidocaine with epinephrine. The prepared tumescent anesthetic bags are suspended from an intravenous pole. Infiltration tubing is connected to the anesthetic bags and then passed through a peristaltic pump. Air is expressed from the infiltration tubing and a small-gauge, blunt-tipped infiltrating cannula or spinal needle is connected. Warming the anesthetic solution to body temperature prior to infiltration may reduce the pain of infiltration.

The anesthetic fluid may initially be infiltrated into the subcutaneous fat using 20-gauge spinal needles. More extensive infiltration is then performed using a blunt-tipped 16- to 18-gauge infiltrating cannula (Fig. 156.8). These small-diameter infiltration cannulas can be passed through tiny incisions created in the skin with a #15c or #11 blade or a 1–2 mm punch. A peristaltic pump facilitates infiltration of the anesthetic fluid into the subcutaneous fat compartment. The cannula must be repositioned to ensure an even distribution of the tumescent anesthetic. Needle movement is associated with increased pain; consequently, a gentle, slow infiltration technique is preferred. In certain areas with more sensitivity, infiltration must be done even more slowly. An infiltration speed of 100 ml/min is usually well tolerated.

Once sufficient tumescent anesthetic has been infiltrated, the surgeon should wait at least 15 minutes to allow for maximal vasoconstrictive effect of the epinephrine. An overlying blanching of the skin will gradually appear. The patient is then properly "tumesced" and ready for aspiration of adipose tissue. Allowing up to an hour between conclusion of infiltration and the onset of suctioning may result in fat removal with even less infranate.

Drug interactions must be considered when using any form of anesthesia[23]. Caution must be exercised with patients on β-blockers, especially non-selective ones. Although rapid absorption of epinephrine may result in hypertension and bradycardia in these patients, when the epinephrine is absorbed slowly, as in the case of tumescent anesthesia, there is minimal risk.

Tumescent anesthesia and certain sedatives may have significant interactions[23]. Some sedatives (such as diazepam) can reduce the rate of lidocaine metabolism after liposuction. Lidocaine is rapidly eliminated by hepatic metabolism, but a number of drugs can inhibit lidocaine metabolism, possibly leading to an increase in lidocaine toxicity[17]. Examples of such drugs are provided in Table 156.5. These medications should be avoided or discontinued prior to liposuction, or the total dose of lidocaine should be reduced.

Surgeons performing tumescent anesthesia should understand the symptoms of lidocaine toxicity and potential treatments (see Ch. 143).

Fig. 156.8 Infiltration of tumescent anesthetic into the previously marked patient. Concentric circles denote areas of increased fat. Sterile towels are positioned to absorb leaking fluid. *Courtesy W.P. Coleman III, MD.*

EXAMPLES OF POSSIBLE DRUG INTERACTIONS WITH LIDOCAINE	
Drug	**Comments**
Anesthetics	
• Bupivacaine	Lidocaine is displaced from plasma binding proteins by bupivacaine
• Halothane plus nitrous oxide	Increase in lidocaine plasma concentration (lowers maximum safe dose)
Amiodarone	Sinus bradycardia, seizures; competes with lidocaine for binding to CYP3A4
Tramadol	Lowers seizure threshold
Phenytoin	Additive cardiac depressant effects
Benzodiazepines, e.g. alprazolam, diazepam	Inhibit lidocaine metabolism
Azole and triazole antifungals, e.g. ketoconazole, itraconazole, fluconazole	Inhibit lidocaine metabolism

Table 156.5 Examples of possible drug interactions with lidocaine. *Adapted from Klein JA. Lidocaine toxicity and drug interactions. In: Tumescent Technique. Tumescent Anesthesia and Microcannular Liposuction. St. Louis: Mosby; 2000.*

Because bupivacaine cardiac toxicity can be subtle, is not preceded by convulsions, and is often unresponsive to resuscitation efforts, bupivacaine is contraindicated for liposuction[24]. In contrast, lidocaine usually gives warning signs of CNS toxicity long before the onset of dangerous cardiotoxic effects. Prilocaine has been used in Europe for tumescent anesthesia instead of lidocaine[25]. However, rigorous comparative studies have not been performed; and, in the US, prilocaine does not have Food and Drug Administration (FDA) approval to be marketed for local anesthesia for dermatologic surgical procedures. Prilocaine can also produce methemoglobinemia[25].

Liposuction surgical technique

The patient is taken to the preoperative area, where he or she changes into surgical garments. Vital signs including blood pressure and heart rate are obtained. Photographs from multiple views should then be taken if they have not been done preoperatively. Areas should be completely unclothed so as not to distort the surgical site(s).

Next, the surgeon marks the patient, who is standing to allow for the effects of gravity. Marking can be done according to the custom of the surgeon, but should be devised so that the subsequent distortion by local anesthetic infiltration will not obscure the various thicknesses of the adiposity. One way to mark is to use concentric circles, as in a topographic map (see Fig. 156.8). Existing dimples and dents should also be outlined for later identification during surgery so that they can be avoided.

Downloaded for Anonymous User (n/a) at Egyptian Knowledge Bank from ClinicalKey.com by Elsevier on March 10, 2024. For personal use only. No other uses without permission. Copyright ©2024. Elsevier Inc. All rights reserved.

The previously marked patient is then positioned on the surgical table. If significant sedation is to be employed, intravenous lines and monitoring devices such as pulse oximeters and cardiac monitors can be utilized. While patients undergoing the tumescent technique usually require very little ancillary sedation, most patients do appreciate pre-sedation with mild oral sedatives such as lorazepam. Those who are pain-sensitive can receive minor additional sedation such as 25 mg of meperidine intramuscularly, a dose which does not impair protective reflexes.

Once the patient is relaxed, tumescent infiltration can begin (see Fig. 156.8). Peristaltic pumps can be regulated for a comfortable rate of infiltration, e.g. 100 ml/min. Of note, more aggressive forms of systemic anesthesia and deeper sedation put patients at higher risk for abdominal perforation. Another disadvantage of deep sedation is that, because of concerns about total anesthesia time, there is usually little or no delay between infiltration and the onset of the procedure leading to less vasoconstriction. As noted previously, significant vasoconstriction from the infiltration of the tumescent fluid does not occur for at least 10–15 minutes after infiltration.

LIPOSUCTION INSTRUMENTATION

The basic instruments required for liposuction are suction cannulas, tubing, and an aspirator[26]. Liposuction can be performed using many different types of cannulas and aspirators. The number of holes arranged along the shaft of the cannula is probably unimportant, although two or more holes increase the flow of fat through the instrument. The most important parameter for choosing cannulas is size: the smallest possible cannula should be employed. Smaller-diameter cannulas (≤3 mm) create smaller tunnels through the fat and achieve smoother results (Fig. 156.9). In addition, smaller-diameter cannulas penetrate the fat more easily and create less tissue trauma. Longer cannulas allow the surgeon to work from fewer skin insertion sites, leaving fewer scars, while shorter cannulas are easier to control as they pass through subcutaneous tissue. The tiny incisions required for insertion of 3 mm cannulas leave nearly invisible scars in most patients, but can be an issue if the patient has a tendency towards keloid formation or hyperpigmentation.

Liposuction is based on the technique of criss-crossing tunnels (from multiple insertion sites) through the subcutaneous tissue. Each area to be suctioned should be tunneled from at least two different directions, but often three or four are more effective. Multiple small tunnels ultimately provide the smoothest contraction of the overlying skin and the most thorough removal of fat. Subsequent contraction of the fatty layer occurs much like a wet sponge contracting into a dry one (Fig. 156.10).

The liposuction aspirate should be yellow or slightly blood-tinged (Fig. 156.11). A red aspirate in the suction tubing indicates excessive bleeding and the surgeon should immediately move on to a different tunnel. The surgeon's instrument hand acts as the piston moving the instrument in and out of the tissue smoothly. The free hand pulls, presses, and squeezes the skin to facilitate penetration of the cannula and provides important tactile information about the thickness of the underlying fat. The final surgical endpoint should be a skin thickness in the suctioned areas which is similar to that of the surrounding untreated skin.

Cannula insertion sites are routinely left open rather than being sutured closed. Closing insertion sites with sutures leads to an increase in postoperative edema due to decreased drainage. The authors generally prefer the use of a #15c blade to create insertion sites leading to less visible scarring. Klein[17] has advocated the use of small 1–2 mm openings made with a punch biopsy instrument.

Liposuction Devices

Ultrasound-assisted

External ultrasound involves preoperative use of an ultrasonic probe over the areas to be suctioned, in an attempt to liquefy or loosen the fat. However, double-blind studies found no benefit to this approach[27]. *Internal* ultrasonic liposuction employs a probe or cannula with an ultrasonic vibration at the tip. These instruments have been shown to liquefy fat prior to suction. Although this makes subsequent liposuction easier, studies have shown increased potential for seromas and burns[28].



Fig. 156.9 A variety of small-diameter liposuction cannulas. The presence of two or more holes increases the flow of fat through the instrument, and while longer cannulas allow the surgeon to work from fewer skin insertion sites, shorter cannulas are easier to control. *Courtesy W.P. Coleman III, MD.*

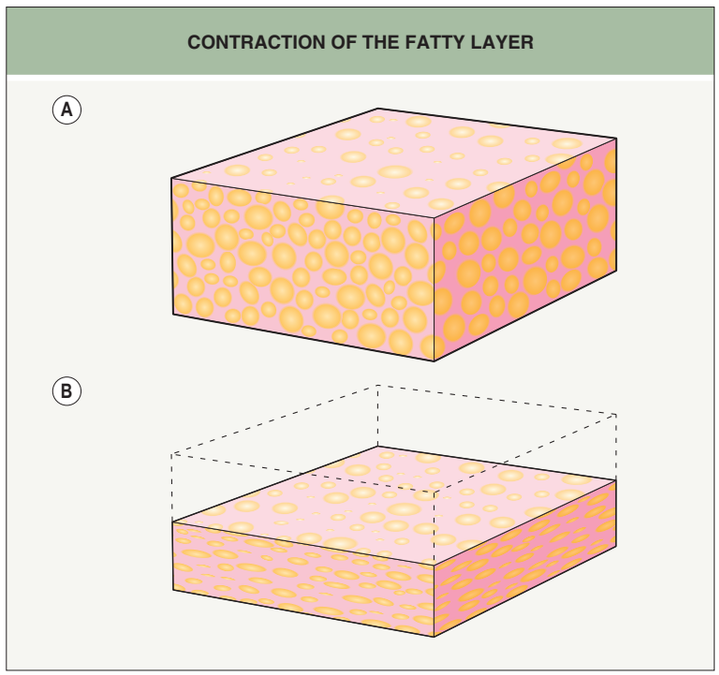

Fig. 156.10 Contraction of the fatty layer. A Immediately after liposuction, the fatty layer resembles a wet sponge. With subsequent subtraction of the fat cells, the thickness of the subcutaneous tissue decreases. **B** Much like a dry sponge, the subcutaneous tissue has compacted.

Fig. 156.11 Bloodless liposuction aspirate. Typical, nearly bloodless liposuction aspirate using the tumescent technique. *Courtesy W.P. Coleman III, MD.*

Downloaded for Anonymous User (n/a) at Egyptian Knowledge Bank from ClinicalKey.com by Elsevier on March 10, 2024. For personal use only. No other uses without permission. Copyright ©2024. Elsevier Inc. All rights reserved.

Ultrasonic probes pass through the tissue like a "hot knife through butter" and do not provide the usual tactile feedback from tissue resistance that manual cannulas do. This makes it difficult for the surgeon to determine in exactly what level of the fat the cannula is located and increases the possibility of intra-abdominal perforation or "end hits" to the opposing dermis. These devices should only be used by experienced surgeons and may be advantageous for skin tightening or if there is excessive fibrous tissue, e.g. gynecomastia.

Power-assisted

These instruments feature a motorized cannula, which moves in a back and forth or swirling motion (Fig. 156.12). The short, motorized strokes vary according to the instrument and allow the surgeon to precisely sculpt small areas of excess fat. Powered liposuction instruments also allow easier penetration of fat, when compared to manual cannulas, but retain some feel of tissue resistance[29]. Studies have shown that powered liposuction increases the fat aspirated (per minute) by 30% or more[29]. There have been no significant complications reported with the use of this approach, although some early users described an increase in seromas. Powered instruments create a larger tunnel than a manual instrument of the same diameter; this should be taken into account when choosing the appropriate size cannula.

Laser-assisted

Laser-assisted devices are designed to transmit infrared laser energy, via a fiber, subcutaneously during liposuction in order to generate heat. Early iterations of these devices had very low power and showed very little difference compared to manual liposuction[30]. Diode and Nd:YAG laser liposuction devices are available from several manufacturers in a variety of wavelengths. Newer devices have higher power and longer wavelengths that are more selective for fat, potentially increasing their efficacy. Benefits include emulsification of fat to make aspiration easier, decreased blood loss[31], and potential for increased skin tightening. The laser fibers can cause burns if used incorrectly, although newer devices have real time temperature feedback mechanisms to reduce this risk. Laser liposuction does take more time to perform and increases costs. Skin tightening seems to be the main purported advantage to these devices. Although this has been difficult to quantify, studies using subcutaneous laser alone have shown significant improvement in skin laxity[32]. However, manual liposuction alone also produces significant tightening and external energy-based tightening devices may provide the same effect.

Radiofrequency-assisted

Several newer devices have employed subcutaneous radiofrequency technology in order to try to increase skin tightening. Some of these devices use monopolar radiofrequency while others use bipolar technology. The purported advantage over laser- and ultrasound-assisted liposuction is better control of the heat produced. Radiofrequency-assisted liposuction has been shown to be safe, but when compared to manual liposuction, enhanced skin contraction is still unproven and a direct comparison trial will be difficult. However, several studies have shown that there is potential for this technology to aid in skin contraction[33].



Fig. 156.12 Reciprocating powered cannula. This reciprocating powered cannula has a 3 mm to-and-fro motion. *From Coleman WP III, Katz B, Bruck M, et al. The efficacy of powered liposuction. Dermatol Surg 2001;27:735–8.*

Water-assisted

These devices employ powerful streams of water directed into the fat layer to create tunnels to facilitate fat removal. Proponents of this approach claim that this reduces the volume of tumescent fluid required. This makes very little sense since the anesthetic effect of the fluid takes several minutes to take effect, long after the tunnel has already been bored by the water jet. There may be potential benefits with this technology when performing fat transplantation as the fat cells may be better preserved than through physical avulsion, but this remains speculative.

Manual liposuction versus device-assisted

The major potential advantage of these devices is skin tightening; however, as stated previously, this is difficult to assess. In patients with more laxity or fibrous tissue, there may be some advantage. However, in individuals with good skin quality, these devices are likely unnecessary as manual liposuction alone provides good skin contraction. Also, it is important to recognize the increased cost associated with using these devices, including disposable costs. Each surgeon needs to determine which instrument he or she is most comfortable with and stick with the approach that is most successful. Each instrument can have a steep learning curve. Excellent liposuction results may be achieved with any of these devices, but only if the surgeon is experienced and well trained.

LIPOSUCTION VARIATIONS

Guidelines of care published by dermatologic organizations recommend that liposuction be performed as a solo procedure and not combined with other techniques[5,6]. However, there are cases in which liposuction is employed as a fundamental part of a combined surgical procedure. For instance, in rhytidectomy, liposuction of the neck and pre-tunneling of the cheeks are often performed prior to flap dissection and advancement. In patients in whom the neck alone is to be treated, liposuction may be combined with submental resection and platysmal plication, with each surgical component contributing to the final result. External light-based and radiofrequency devices may also be combined with neck liposuction to improve skin contraction.

In other anatomic sites, skin excision may be combined with liposuction. Where there is a significant abdominal panniculus, a suprapubic incision may be used to remove excess skin in conjunction with liposuction of the rest of the abdomen. However, in most patients with a moderate panniculus, this may be unnecessary because of the significant skin retraction that occurs after liposuction of the lower abdomen. Experience shows that most patients who consult for abdominoplasty achieve excellent results with liposuction alone. Abdominoplasty is a much more aggressive procedure, with significantly increased morbidity and mortality. The final scar is significant and often unattractive as well.

Liposuction is an excellent option for improvement of pseudogynecomastia in men. In these patients, the breast enlargement results primarily from excess fat rather than the excess glandular tissue present in true gynecomastia. Aggressive liposuction is required to remove what is usually thicker and more fibrotic fat. Powered or ultrasonic liposuction is sometimes useful in tunneling through this more fibrous fat. In patients with true gynecomastia, the glandular tissue must also be removed, usually through a submammary or periareolar incision, to obtain sufficient flattening of the breast. Liposuction can also be used for moderate breast reduction in females. The best results are seen in women with soft breasts. Very firm glandular breasts of younger patients do not respond well to liposuction, nor do ptotic breasts, which may sag more after the procedure. These patients are better served with excisional breast reduction.

NON-COSMETIC LIPOSUCTION

Liposuction may also be used for non-cosmetic indications (see Table 156.1). The chief among these are hyperhidrosis and lipoma removal[11]. When topical preparations are ineffective, botulinum toxin injections, sympathectomy, external focused microwave, and liposuction can be performed. For axillary hyperhidrosis, subdermal liposuction is used aggressively to remove as much of the subdermal fat in the axilla

Downloaded for Anonymous User (n/a) at Egyptian Knowledge Bank from ClinicalKey.com by Elsevier on March 10, 2024. For personal use only. No other uses without permission. Copyright ©2024. Elsevier Inc. All rights reserved.

as possible (see Fig. 156.7). Since many of the eccrine and apocrine sweat glands reside in the upper fat, liposuction can diminish sweating postoperatively. The goal is to make the patient sweat normally, but not to become anhidrotic. Preoperatively, a starch iodine test identifies the areas of greatest sweating (see Ch. 39). The liposuction should be aggressive enough to create some subdermal fibrosis, in an attempt to eliminate as many dermal eccrine and apocrine structures as possible. Patients are usually comfortable within 24 hours and able to resume normal activities within 2–3 days. Often, there is immediate diminished sweating with a rebound 2–3 weeks postoperatively, followed by a gradual decrease in sweating as fibrosis develops in the subdermal region.

Larger lipomas can also be reduced efficiently using liposuction. The goal here is to flatten out the lipoma but not necessarily remove the entire lesion. The advantage of liposuction over standard excisional surgery is that the former leads to a much smaller scar. As with any adiposity, the lipoma is tunneled in a criss-cross direction until flat. Subsequent healing and fibrosis usually flattens the remaining lipoma further, resulting in a normal contour. It is difficult to suction smaller lipomas and these are best removed through direct puncture excision. However, lipomas the size of a golf ball or larger are excellent candidates for liposuction. Since the entire lesion is not surgically removed, lipomas treated in this fashion may be more likely to recur; the patient should be made aware of this possibility. Liposuction should be reserved for lesions that are in cosmetically sensitive areas or those of a size which would necessitate a larger incision.

POSTOPERATIVE CARE

Following liposuction, patients are usually quite comfortable during the initial postoperative period. It is important to remind patients, well before the procedure takes place, that they are going to have significant drainage for the first day following liposuction surgery. Barrier protection is recommended for car seats, furniture, and bed linens during this period.

The patient's insertion sites may be coated with petrolatum or antibiotic ointment prior to application of absorbent materials. Modern absorbent pads are capable of absorbing significant amounts of drainage from the insertion sites thereby decreasing the need for patients to change pads. Most individuals will experience continued drainage for 24–48 hours following liposuction. Patients are advised to take their first shower with the absorbent bandages and the tape in place, as the shower assists in the removal of the tape.

Following the application of sufficient amount and layers of absorbent pads, a compression garment or a compression bandage is fitted. Numerous styles of postoperative liposuction compression garments are available. Postoperative compression minimizes bruising and aids in drainage. Gravitational drainage minimizes postoperative edema. It is important to use firm compression immediately following tumescent liposuction[34]. Compression assists patients in feeling more secure and decreases pain by restricting movement of the treated tissue. Many patients actually enjoy the comfort and feel of a compression garment due to the soreness sometimes associated with movement in the immediate postoperative period. Patients with pre-existing laxity or large amounts of fat removal may benefit from a longer period of compression.

Infections have occasionally been reported with liposuction and oral antibiotics may provide prophylaxis against more serious infections. Of note, lidocaine is bactericidal[35]. This may explain, in part, the relatively few infections seen with tumescent liposuction. Careful local wound care and cleanliness are essential in producing a good liposuction outcome.

Most patients can return to work within 48 hours following their liposuction. It is important to ask the patients to ambulate regularly beginning the day after surgery. This movement encourages drainage as well as remodeling of the subcutaneous tissue. Movement has the additional benefit of increasing lymphatic drainage through intermittent pumping action of skeletal muscles. Light exercise may begin 24–48 hours after surgery, but patients should be advised to start at 25% of their normal routine. Generally, patients are back to normal exercise routines after the first postoperative week.

All patients are given a set of written postoperative liposuction instructions including important phone numbers should the patient need to contact the physician. These postoperative instructions remind the patient that swelling and firmness beneath the skin and a reduced sensation in the skin are common. This will usually resolve over the first 3 to 4 weeks after the surgery. The postoperative instructions also remind patients that the final results are not seen until 6–12 months following the liposuction.

Patients return for their first postoperative appointment 1 day following liposuction. This visit is important to check for problems and reassure the patient. The next visit usually occurs during the first 3 weeks. It is often necessary to remind patients that improvement from liposuction is a gradual process. This postoperative visit is a good opportunity for encouraging patients to exercise, maintain an active and healthy lifestyle, and eat a reasonable diet. Patients are seen for 3-month and 6-month follow-up visits. If touch-ups are required, it is wise to wait 1 year before proceeding to be certain that the final results have been achieved. Secondary liposuctions that are performed too early in the postoperative period may lead to skin irregularities.

COMPLICATIONS OF LIPOSUCTION

Complications of liposuction must be differentiated from common sequelae. After liposuction, it is common to have prolonged swelling, areas of numbness, bruising, and red incisions. Infections, hematomas, and seromas are rare complications that require medical attention but can usually be resolved rapidly.

Serious complications of liposuction are closely linked to the type of sedation employed. There have been a number of deaths from liposuction in patients who had moderate or deep sedation[18,19,36]. The authors are not aware of any deaths from liposuction in patients who underwent the procedure with true tumescent local anesthesia[37].

Deep vein thrombosis and pulmonary embolism postoperatively are surgical complications generally associated with non-ambulatory patients and prolonged procedures under general anesthesia. An advantage of the tumescent local anesthetic technique is that patients are ambulatory immediately after surgery, thus minimizing the risk of this potential problem. Patients who are obese and inactive are more at risk for the development of this complication; this should be taken into consideration during the preoperative evaluation.

Abdominal perforation is one of the leading causes of liposuction death[38]. This is exclusively a complication of liposuction under general anesthesia[20]. Deeply sedated patients have decreased muscle tone and are unable to alert the physician to the pain of penetration of the liposuction cannula. Occult abdominal hernias may contribute to this complication. The treating physician should be aware of any abdominal scars and palpate for hernias during the preoperative visit.

General anesthesia also increases risks of respiratory failure and cardiac death[22]. Besides the direct effect of systemic anesthesia, fluid overload may contribute to these problems. Anesthesiologists who are not accustomed to working with patients who have been infiltrated with tumescent anesthetic fluids may inadvertently overhydrate the patient with additional intravenous fluids. A significant amount of the saline infused subcutaneously is absorbed systemically, automatically correcting for surgical fluid losses. Compounding this problem is the discovery that intravenous fluid bags are typically overfilled by at least 10%, leading to further errors in calculating fluid replacement in liposuction[39].

The keys to avoiding complications in liposuction lie in proper patient selection, appropriate patient evaluation, realistic patient expectations, monitoring according to the degree of sedation, good surgical technique, avoidance of excessive fat removal or overzealous additional simultaneous procedures, and adequate postoperative care.

NON-INVASIVE BODY CONTOURING

Liposuction is now a mature procedure and most patients obtain predictable results[40,41]. However, as with all cosmetic procedures, there is a general trend toward trying to accomplish similar results with less invasive techniques. Several non-invasive modalities are currently approved for the treatment of localized subcutaneous fat (Table 156.6). Some of these treatments, such as injection lipolysis, have been in existence for many years, but recently have garnered more interest; other technologies, such as external ultrasonic devices, external cryolipolysis, external radiofrequency, and low-level light treatments, are relative newcomers to the field.

Downloaded for Anonymous User (n/a) at Egyptian Knowledge Bank from ClinicalKey.com by Elsevier on March 10, 2024. For personal use only. No other uses without permission. Copyright ©2024. Elsevier Inc. All rights reserved.

NON-INVASIVE BODY CONTOURING MODALITIES	
Non-invasive modality	**Mechanism of action**
Injection lipolysis (deoxycholate)	Fat cell membrane disruption (adipocytolysis)
High-intensity focused ultrasound	Thermal destruction of adipocytes
Non-thermal focused ultrasound	Cavitation disruption of adipocytes
Cryolipolysis	Cold-induced apoptosis/panniculitis
Radiofrequency (mono-, uni-, bi-, tri-polar)	Thermal destruction of adipocytes
Low level light therapy	Photochemical membrane pore creation (theoretical)

Table 156.6 Non-invasive body contouring modalities.

Fig. 156.13 Phosphatidylcholine/deoxycholate injection to the submental area. A Pre-treatment. **B** 1 month post-treatment, showing improved contour of the neck. *Courtesy K.M. Coleman, MD.*

Injection Lipolysis

Mesotherapy, which was originally developed in the 1950s, has re-emerged as a treatment for localized adiposities. Most commonly, this technique involves the subcutaneous injection of a formulation containing phosphatidylcholine plus a detergent solvent that leads to the dissolution of fat cells[42]. More recent work has shown that the detergent solvent, usually deoxycholic acid, is more likely the active ingredient in this solution[43]. Deoxycholic acid works by causing adipocytolysis, leading to a decrease in fat volume via contraction and remodeling. In 2015, deoxycholic acid was approved by the FDA for the reduction of moderate to severe submental fullness. The injections consist of small aliquots (0.1–0.2 ml) placed ~1 cm apart from each other[44]. Treatment volume used varies depending on the amount of adiposity present. Most patients will require several treatments, at least one month apart, for best results. Of note, many physicians are lengthening the time between sessions to allow post-treatment edema to subside more completely prior to the next set of injections. Full results are not apparent until 12 weeks post-therapy (Fig. 156.13).

Post-treatment sequelae include edema, ecchymoses, decreased sensation, and hair loss. For most patients, edema is self-limited but in some instances, persistent edema may occur necessitating treatment with intralesional triamcinolone acetonide or anti-inflammatory medications. Post-treatment edema tends to lessen with subsequent deoxycholic acid injections.

There have been several reports of off-label use of deoxycholic acid, including for jowls, pre- and post-axillary bra fat, suprapatellar fat pads, and small truncal adiposities[45,46]. The therapeutic efficacy of deoxycholic acid injections is limited to smaller adiposities. Its use for larger areas has not been established and would not be clinically or financially feasible.

Low Level Light Therapy (LLLT)

An external 635 nm diode laser (Zerona™; Erchonia) is FDA-cleared for fat reduction around the waist. Theoretically, this device reduces the size of subcutaneous fat by induction of a photochemical reaction which creates small pores in the adipocyte cell membrane[47]. However, early reports of the results of these treatments had only short follow-up times and no weight control. In addition, several studies have shown that the minimal results produced seem to abate over time, with long-term results still in question as well.

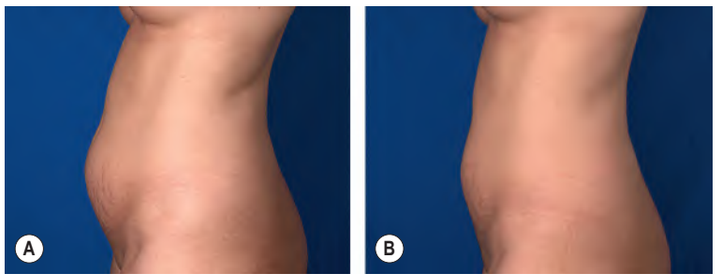

Fig. 156.14 Non-thermal focused ultrasound (UltraShape™) treatment of the abdomen. A Pre-treatment. **B** 42 days post-treatment.

High-Intensity Focused Ultrasound

High-frequency ultrasound, HIFU (LipoSonix™; Innovations Medical), relies upon ultrasound-induced thermal destruction of adipocytes. This device is based on technology currently employed in the treatment of malignant tumors, in particular prostate cancer. The ultrasound has a focal depth of 1.3 cm and creates tissue temperatures up to about 70°C. The thermal destruction of adipocytes at this depth leads to tissue contraction and reduction of adiposities over an 8- to 12-week period[48]. The FDA cleared this technology for non-invasive waist circumference reduction in 2011 and reduction in waist circumference from a single treatment has been reported to be about 2–3 cm. Patients complain of discomfort during the treatments which can be moderate to severe in some. The most common sequelae from HIFU include post-procedural pain, numbness, edema, and ecchymoses.

Non-thermal Focused Ultrasound

Non-thermal, external ultrasound (UltraShape Power®; Candela™) produces targeted cavitation of fat cells without producing significant heating; this allows the device to achieve lipolysis without creating damage to blood vessels and nerves[49,50]. Disruption of the adipocytes leads to release of fatty acids. The device has been cleared by the FDA for abdominal circumference reduction. Treatments are performed every 2 weeks; generally, 3 treatments are recommended. During treatment, patients experience minimal if any discomfort. The focal depth of the ultrasound is 1.5 cm and care should be taken over bony prominences to avoid reflection of the waves.

Post-procedural sequelae are rare and are likely related to technique. Blistering can result from inadequate contact with the device or treatment over a bony area. Patients may resume all activities immediately after treatments and generally have no pain, edema, or bruising. Patients are advised to avoid excessive fat consumption during the first 2 days post-procedure. Treatment results appear gradually with improvement over a 6- to 8-week period. After 3 treatments, an average reduction in waist circumference of 3–5 cm has been reported (Fig. 156.14).

Cryolipolysis

Cryolipolysis (Coolsculpting®; Zeltiq Aesthetics) involves the targeted production of adipocyte apoptosis via thermal energy extraction (without damage to the epidermis). Porcine and human trials have shown significant reduction in subcutaneous fat. This device utilizes vacuum suction to elevate tissue into contact with cooling plates within the device[51,52]. There are now several different applicators to fit different body types and areas. The treatment involves placing the treatment applicator over the selected area and starting the vacuum and cooling process; the applicator remains in place for 1 hour. Separate body areas can be treated at the same time or sequentially. Current recommendations are to retreat the area in 1 month, with results occurring gradually over a period of 2–3 months.

During the treatment, there is mild discomfort. Immediately after treatment, the treated area is cold and indurated; this resolves over about thirty minutes (Fig. 156.15). A randomized trial has shown that vigorous massage of the treated tissue can lead to greater reduction in

Downloaded for Anonymous User (n/a) at Egyptian Knowledge Bank from ClinicalKey.com by Elsevier on March 10, 2024. For personal use only. No other uses without permission. Copyright ©2024. Elsevier Inc. All rights reserved.

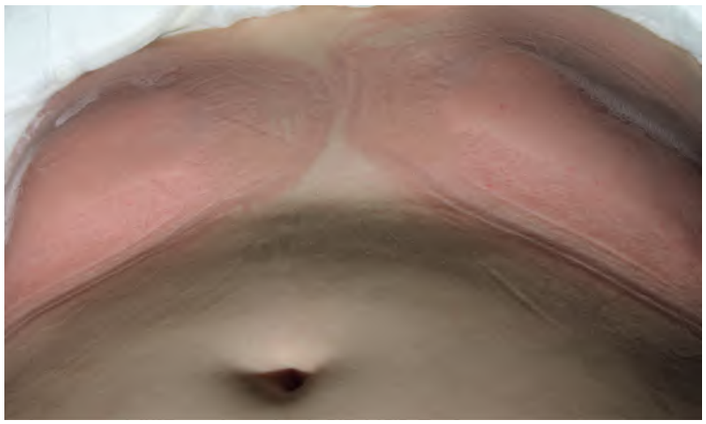

Fig. 156.15 Immediate post-treatment response of cryolipolysis. The treated skin is elevated, cold to the touch, clay-like, and erythematous.

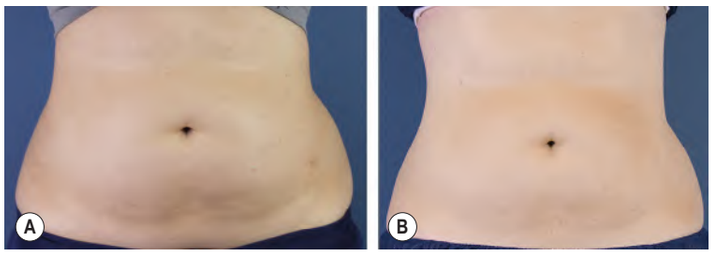

Fig. 156.16 Cryolipolysis (Coolsculpting®) of the abdomen. A Pre-treatment. **B** 6 months later, after 2 treatments. *Courtesy K.M. Coleman, MD.*

adiposities. Commonly, there is some erythema for the first few hours; patients complain of transient pain, numbness, bruising, and edema, which all generally resolve over 2 weeks. Rarely, prolonged pain can occur; this usually responds to oral anti-inflammatory agents. There have been several reports of paradoxical adipose hyperplasia which may require liposuction for correction[53]. Results of these treatments is highly dependent on proper patient selection and proper application of the device (Fig. 156.16). Multiple treatment tips are usually needed to adequately treat an area.

Radiofrequency

Radiofrequency devices utilize an oscillating electrical field to create heat in target tissues; lower frequencies are able to penetrate more deeply. Several radiofrequency devices are available for multiple aesthetic uses. Devices can be monopolar or unipolar (1 electrode), bipolar, or multipolar. For fat reduction, results with radiofrequency devices have been mixed with some newer devices reportedly more successful.

A selective, contactless radiofrequency device (Vanquish Me™; BTL Aesthetics) uses focused field radiofrequency to target adiposities. A prospective trial showed a 4.93 cm reduction in abdominal circumference after 4 weekly treatments; however, 3 patients showed no reduction at all[54]. Use of a vacuum-assisted bipolar device that utilizes software to maintain constant temperature control (Evolve®; Inmode) led to a 2.7 cm decrease in abdominal circumference after 6 weekly treatments[55]. Currently, this device combines non-vacuum bipolar heads with suction-assisted heads in order to treat more superficial adiposity and skin laxity.

CELLULITE

Cellulite is a common problem for most women with variable presentations. It can present as dimples, rippling of the skin, and/or superficial adiposities. The morphology of cellulite stems from superficial fat deposits, skin laxity, and perpendicular dermal bands which lead to dimpling. For years, treatment options have been less than satisfying in their durability and effectiveness. However, more recently introduced technologies have shown promise for providing durable improvement in the appearance of cellulite (Table 156.7).

CELLULITE TREATMENT OPTIONS	
Treatment	**Mechanism of action**
Manual subcision*	Manual release of dermal bands
External radiofrequency	Skin tightening, reduction of superficial adiposity
Subdermal side-firing (1440 nm Nd:YAG) laser	Release of dermal bands, skin tightening, reduction of adiposity
Subdermal radiofrequency	Skin tightening, reduction of adiposity
Vacuum-assisted subcision	Controlled release of dermal bands
Injectable collagenase	Lysis of dermal bands

*Sometimes followed by injection of fillers such as calcium hydroxylapatite and poly-L-lactic acid microspheres.

Table 156.7 Cellulite treatment options.

Fig. 156.17 Subdermal laser treatment (Cellulaze®) of posterior thigh cellulite. A Pre-treatment. **B** 6 months post-treatment. *Courtesy K.M. Coleman, MD.*

External Devices

There are several commercially available external treatments that attempt to improve cellulite. Most of them are minimally, if at all, effective in providing long-term improvement. For example, body wraps and massages can temporarily improve the appearance of cellulite, but there is no durable improvement. Most of the devices employed for the external treatment of cellulite rely on radiofrequency-induced heat to tighten skin and reduce superficial adiposity. Because these devices only address two of the three causes of cellulite – laxity and superficial adiposity – their effectiveness is limited. They require numerous treatment sessions to produce any improvement and results tend to not be durable.

Rapid Acoustic Pulse™ technology, which utilizes high intensity, high frequency, ultrashort acoustic wave pulses, is said to be capable of disrupting fascial connections, rendering the dimpling less evident. However, the results may not be durable beyond the treatment period.

Subdermal Devices

Since cellulite is created by subdermal bands and adiposity, these devices target the subdermal plane. This approach is minimally invasive and generally performed with tumescent anesthesia. The first device that incorporated subdermal treatment of cellulite was the 1440 nm side-firing laser (Cellulaze®; Cynosure). Its laser fibers are designed to refract the beam into two perpendicular beams which allow for treatment in two directions. One beam treats skin laxity and superficial adiposity while the second helps to cut the cellulite bands. Although results have been mixed, some authors have reported very good results that were durable (Fig. 156.17)[56]. Other subdermal technologies such as radiofrequency devices can be used in patients with cellulite; however, they address the laxity and superficial adiposity without cutting the dermal bands.

Subcision

Manual subcision of cellulite dimples has long been effective in some physicians' hands. When performed by those experienced in this technique, durable results have been observed. Subcision is generally performed with an 18-gauge filter needle under local anesthesia.

Downloaded for Anonymous User (n/a) at Egyptian Knowledge Bank from ClinicalKey.com by Elsevier on March 10, 2024. For personal use only. No other uses without permission. Copyright ©2024. Elsevier Inc. All rights reserved.

The needle is used to horizontally cut the dermal bands and release the dimples.

Vacuum-assisted subcision

Since manual subcision can be technically challenging and time-consuming, attempts have been made to enhance effectiveness and reproducibility. With a vacuum-assisted subcision device (cellfina®; Merz Aesthetics), the vacuum secures and elevates the tissue with the dimple, allowing for insertion of an oscillating blade into the correct tissue plane to release the dermal bands[57]. This leads to more exact targeting of the dermal bands and more rapid treatments. Results have been reported as very durable, lasting up to several years. As these vacuum-assisted devices only target dermal bands, they work best for dimpled cellulite and are not very effective in patients with laxity or rippled cellulite.

Fat Transfer and Fillers

For severe dimpling of cellulite, subcision of dimples alone may not be sufficient. Placement of fat or fillers can help to further smooth these lesions. Based upon their collagen stimulatory properties, fillers such as calcium hydroxylapatite and poly-L-lactic acid microspheres are also being used to treat cellulite[58]. They are injected in a dilute fashion in order to improve skin laxity.

Collagenase

Injectable collagenase (Qwo®; Endo Pharmaceuticals) is the most recent addition to the therapeutic armamentarium for cellulite, and it has shown some promise in clinical trials[59]. In order to release dimpling, the collagenase is injected into dermal bands. There is no need for anesthesia and serial injections are performed every 3 to 4 weeks per current protocols. However, the latter may undergo further revisions. Based upon early results, improvement may be durable (up to at least 2 years). A significant drawback is the potential for developing large ecchymoses that lead to hemosiderin deposition in some patients.

CONCLUSION

Technology is constantly providing physicians with new ways to minimize localized adiposities. Regardless of what instrumentation is used, it is likely that in the future liposuction will remain one of the most popular and predictable cosmetic procedures. As more non-invasive treatments become available, it is important to recognize the pros and cons of each of these devices. No matter which type of treatment is performed, the single most important aspect in choosing a therapy is patient selection.

Additional figures available in our eBook (see inside front cover for access code).

REFERENCES

1. Fischer A, Fischer G. First surgical treatment for molding body's cellulite with three 5 mm incisions. *Bull Int Acad Cosmet Surg*. 1976;3:35.
2. Illouz YG. Body contouring by lipolysis: a 5-year experience with over 3000 cases. *Plast Reconstr Surg*. 1983;72:591–597.
3. Fournier PF, Otteni FM. Lipodissection in body sculpturing: the dry procedure. *Plast Reconstr Surg*. 1983;72:598–609.
4. Flynn TC, Narins RS. Preoperative evaluation of the liposuction patient. *Dermatol Clin*. 1999;17:729–734.
5. Coleman III WP, Glogau RG, Klein JA, et al. Guidelines of care of liposuction. *J Am Acad Dermatol*. 2001;45:438–447.
6. Lawrence N, Clark RE, Flynn TC, Coleman III WP. American Society for Dermatologic Surgery Guidelines of Care for Liposuction. *Dermatol Surg*. 2000;26:265–269.
7. Klein JA. Tumescent technique for liposuction surgery. *Am J Cosmet Surg*. 1987;4:263–267.
8. Klein JA. Tumescent technique for regional anesthesia permits lidocaine doses of 35 mg/kg for liposuction. *J Dermatol Surg Oncol*. 1990;16:248–263.
9. Ostad A, Kageyama N, Moy RL. Tumescent anesthesia with a lidocaine dose of 55 mg/kg is safe for liposuction. *Dermatol Surg*. 1996;22:921–927.
10. Coleman III WP. Tumescent anesthesia with a lidocaine dose of 55 mg/kg is safe for liposuction (editorial). *Dermatol Surg*. 1996;22:919.
11. Coleman III WP. Noncosmetic applications of liposuction. *J Dermatol Surg Oncol*. 1988;14:1085–1090.
12. Chastain MA, Chastain JB, Coleman III WP. HIV lipodystrophy: review of the syndrome and report of a case treated with liposuction. *Dermatol Surg*. 2001;27:497–500.
13. Coleman III WP, Letessier S, Hanke CW. Liposuction. In: Coleman III WP, Hanke CW, Alt TH, Asken S, eds. *Cosmetic Surgery of the Skin*. St Louis: Mosby; 1997:178–205.
14. Lillis PJ. Liposuction surgery under local anesthesia: limited blood loss and minimal lidocaine absorption. *J Dermatol Surg Oncol*. 1988;14:1145–1148.
15. Klein JA. Anesthetic formulation of tumescent solutions. *Dermatol Clin*. 1999;17:751–759.
16. Klein JA. Tumescent technique for local anesthesia improves safety in large-volume liposuction. *Plast Reconstr Surg*. 1993;92:1085–1098; discussion 1099–1100.
17. Klein JA. *Tumescent Technique. Tumescent Anesthesia and Microcannular Liposuction*. St Louis: Mosby; 2000.
18. Coleman III WP, Hanke CW, Glogau RG. Does the specialty of the physician affect fatality rates in liposuction? A comparison of specialty specific data. *Dermatol Surg*. 2000;26:611–615.
19. Rao RB, Ely SF, Hoffman RS. Deaths related to liposuction. *N Engl J Med*. 1999;30:1471–1475.
20. Coleman III WP, Hanke CW, Lillis P, et al. Does the location of the surgery or the specialty of the physician affect malpractice claims in liposuction? *Dermatol Surg*. 1999;25:343–347.
21. Hanke CW, Bernstein G, Bullock S. Safety of tumescent liposuction in 15,336 patients. National survey results. *Dermatol Surg*. 1995;21:459–462.
22. Forrest JB, Rehder K, Cahalan MK, Goldsmith CH. Multicenter study of general anesthesia. III. Predictors of severe perioperative adverse outcomes. *Anesthesiology*. 1992;76:3–15.
23. Klein JA, Kassarjdian N. Lidocaine toxicity with tumescent liposuction. A case report of probable drug interactions. *Dermatol Surg*. 1997;23:1169–1174.
24. Klein JA. Intravenous fluids and bupivacaine are contraindicated in tumescent liposuction. *Plast Reconstr Surg*. 1998;102:2516–2519.
25. Breuninger H, Wehner-Caroli J. Subcutaneous infusion anesthesia with prilocaine diluted with Ringer's lactate. *Hautarzt*. 1998;49:709–713.
26. Bernstein G. Instrumentation for liposuction. *Dermatol Clin*. 1999;17:735–749.
27. Lawrence N, Coleman III WP. Ultrasonic-assisted liposuction. Internal and external. *Dermatol Clin*. 1999;17:761–771.
28. Lawrence N, Coleman III WP. The biologic basis of ultrasonic liposuction. *Dermatol Surg*. 1997;23:1197–1200.
29. Coleman III WP, Katz B, Bruck M, et al. The efficacy of powered liposuction. *Dermatol Surg*. 2001;27:735–738.
30. Prado A, Andrades P, Danilla S, et al. A prospective, randomized, double-blind, controlled clinical trial comparing laser-assisted lipoplasty with suction-assisted lipoplasty. *Plast Reconstr Surg*. 2006;118:1032–1045.
31. Abdelaal MM, Aboelatta YA. Comparison of blood loss in laser lipolysis vs traditional liposuction. *Aesthet Surg J*. 2014;34:907–912.
32. Sarnoff DS. Evaluation of the safety and efficacy of a novel 1440nm Nd:YAG laser for neck contouring and skin tightening without liposuction. *J Drugs Dermatol*. 2013;12:1382–1388.
33. Theodorou SJ, Del Vecchio D, Chia CT. Soft tissue contraction in body contouring with radiofrequency-assisted liposuction: a treatment gap solution. *Aesthet Surg J*. 2018;38:S74–S83.
34. Klein JA. Post-tumescent liposuction care. Open drainage and bimodal compression. *Dermatol Clin*. 1999;17:881–889.
35. Klein JA. Antibacterial effects of tumescent lidocaine. *Plast Reconstr Surg*. 1999;104:1934–1936.
36. Grazer FM, de Jong RH. Fatal outcomes from liposuction: census survey of cosmetic surgeons. *Plast Reconstr Surg*. 2000;105:436–446; discussion 447–8.
37. Hanke W, Cox SE, Kuznets N, Coleman 3rd WP. Tumescent liposuction report performance measurement initiative: national survey results. *Dermatol Surg*. 2004;7:967–977.
38. Talmor M, Hoffman LA, Lieberman M. Intestinal perforation after suction lipoplasty: a case report and review of the literature. *Ann Plast Surg*. 1997;38:169–172.
39. Coleman IV WP, Flynn TC, Coleman KL. When one liter does not equal 1000 milliliters: implications for the tumescent technique. *Dermatol Surg*. 2000; 26:1024–1028.
40. Yoho RA, Romaine JJ, O'Neil D. Review of the liposuction, abdominoplasty, and face-lift mortality and morbidity risk literature. *Dermatol Surg*. 2005;31:733–743.
41. Shiffman MA, Di Giuseppe A. *Liposuction: Principles and Practice*. Berlin: Springer-Verlag; 2006.
42. Rotunda AM, Kolodney MS. Mesotherapy and phosphatidylcholine injections: historical clarification and review. *Dermatol Surg*. 2006;32:465–480.
43. Rotunda AM, Weiss SR, Rivkin LS. Randomized double-blind clinical trial of subcutaneously injected deoxycholate versus a phosphatidylcholine-deoxycholate combination for the reduction of submental fat. *Dermatol Surg*. 2009;35:792–803.
44. Rzany B, Griffiths T, Walker P, et al. Reduction of unwanted submental fat with ATX-101 (deoxycholic acid), an adipocytolytic injectable treatment: results from a phase III, randomized, placebo-controlled study. *Br J Dermatol*. 2014;170:445–453.
45. Montes J, Santos E, Chillar A. Jowl reduction with deoxycholic acid. *Dermatol Surg*. 2020;46:78–85.
46. Zarbafian M, Fabi S. Off-label uses of deoxycholic acid in body contouring. *Dermatol Surg*. 2020;46:S2–S7.
47. Neira R, Arroyave J, Ramirez H, et al. Fat liquefaction: effect of low-level laser energy on adipose tissue. *Plast Reconstr Surg*. 2002;110:912–922.
48. Jewell ML, Weiss RA, Baxter RA, et al. Safety and tolerability of high-intensity focused ultrasonography for noninvasive body sculpting: 24-week data from a randomized, sham-controlled study. *Aesthet Surg J*. 2012;32:868–876.
49. Teitelbaum SA, Burns JL, Kubota J, et al. Noninvasive body contouring by focused ultrasound: safety and efficacy of the Contour I device in a multicenter, controlled, clinical study. *Plast Reconstr Surg*. 2007;120:779–789.
50. Moreno-Moraga J, Valero-Altés T, Riquelme AM, et al. Body contouring by non-invasive transdermal focused ultrasound. *Lasers Surg Med*. 2007;39:315–323.
51. Manstein D, Laubach H, Watanabe K, et al. Selective cryolysis: a novel method of non-invasive fat removal. *Lasers Surg Med*. 2008;40:595–604.
52. Zelickson B, Egbert BM, Preciado J, et al. Cryolipolysis for noninvasive fat cell destruction: initial results from a pig model. *Dermatol Surg*. 2009;35:1462–1470.
53. Hedayati B, Juhász M, Chu S, et al. Adverse events associated with cryolipolysis: a systematic review of the literature. *Dermatol Surg*. 2020;46:S8–S13.
54. Fajkošová K, Machovcová A, Onder M, et al. Selective radiofrequency therapy as a non-invasive approach for contactless body contouring and circumferential reduction. *J Drugs Dermatol*. 2014;13:291–296.

Downloaded for Anonymous User (n/a) at Egyptian Knowledge Bank from ClinicalKey.com by Elsevier on March 10, 2024. For personal use only. No other uses without permission. Copyright ©2024. Elsevier Inc. All rights reserved.

55. Boisnic S, Divaris M, Nelson AA, et al. A clinical and biological evaluation of a novel, noninvasive radiofrequency device for the long-term reduction of adipose tissue. *Lasers Surg Med*. 2014;46:94–103.
56. Alexiades M, Munavalli G, Goldberg D, et al. Prospective multicenter clinical trial of a temperature-controlled subcutaneous microneedle fractional bipolar radiofrequency system for the treatment of cellulite. *Dermatol Surg*. 2018;44:1262–1271.
57. Kaminer M, Coleman W, Weiss R, et al. Multicenter pivotal study of vacuum-assisted precise tissue release for the treatment of cellulite. *Dermatol Surg*. 2015;41:336–347.
58. Coleman KM, Pozner J. Combination therapy for rejuvenation of the outer thigh and buttock: a review and our experience. *Dermatol Surg*. 2016;42(Suppl 2): S124–130.
59. Sadick N, Goldman M, Liu G. Collagenase *Clostridium histolyticum* for the treatment of edematous fibrosclerotic panniculopathy (cellulite): a randomized trial. *Dermatol Surg*. 2019;45:1047–1056.

Downloaded for Anonymous User (n/a) at Egyptian Knowledge Bank from ClinicalKey.com by Elsevier on March 10, 2024. For personal use only. No other uses without permission. Copyright ©2024. Elsevier Inc. All rights reserved.

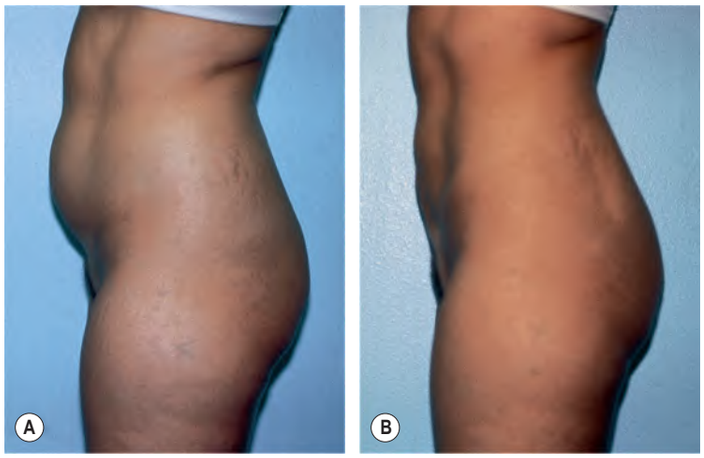

eFig. 156.1 Liposuction of the upper and lower abdomen. A Preoperative. **B** Postoperative, showing improved contours. *Courtesy W.P. Coleman III, MD.*

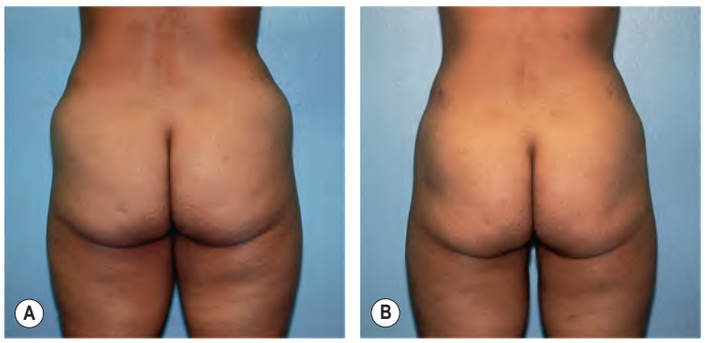

eFig. 156.2 Liposuction of the inner and outer thighs and hips. A Preoperative. **B** Postoperative, showing improved contours. *Courtesy W.P. Coleman III, MD.*

eFig. 156.3 Liposuction of the neck and jowls. A Preoperative. **B** Postoperative, showing improved appearance. *Courtesy W.P. Coleman III, MD.*

eFig. 156.4 Peristaltic pump for infiltration of tumescent anesthetic mixtures. *Courtesy K.M. Coleman, MD.*

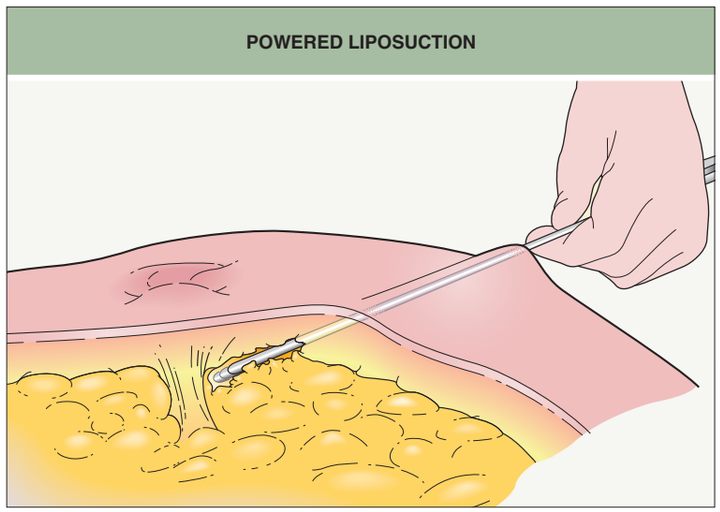

eFig. 156.5 Powered liposuction. Using powered liposuction to more precisely sculpt small areas of fat around the umbilicus.

eFig. 156.6 Examples of liposuction compression garments. *Courtesy Miller Medical, Tucson, AZ.*

Downloaded for Anonymous User (n/a) at Egyptian Knowledge Bank from ClinicalKey.com by Elsevier on March 10, 2024. For personal use only. No other uses without permission. Copyright ©2024. Elsevier Inc. All rights reserved.